

**Original Research Article****Amalgam and Composite Use among Dental Students in Saudi Arabia**

Authors

**Rahaf Al-Safadi,<sup>1,2\*</sup> Riham Al-Safadi, Noor Al-Lowaim,<sup>2</sup> Fatimah Al-Alwi,<sup>2</sup>  
Duaa Al-Yahya,<sup>2</sup> Bayan Al-Shallaa,<sup>2</sup> Ghadeer Al-Ghanim,<sup>2</sup> Dina Al-Ismail,<sup>2</sup>  
Fatimah Al-Haddad<sup>2</sup>**

<sup>1</sup>Department of Preventive Dentistry, College of Dentistry, Riyadh Elm University, Riyadh, Kingdom of Saudi Arabia

<sup>2</sup>University Dental Hospital, College of Dentistry, Riyadh Elm University, Riyadh, Kingdom of Saudi Arabia

\*Corresponding Author

**Rahaf Al-Safadi**

Department of Preventive Dentistry, University Dental Hospital, College of Dentistry, Riyadh Elm University, Riyadh, Kingdom of Saudi Arabia

Email: [dent.sci.research@gmail.com](mailto:dent.sci.research@gmail.com)

**Abstract**

**Aim:** *The aim of this study was to detect the use of resin composite and amalgam restorations placed in permanent posterior teeth by undergraduate dental students in university dental hospitals in Saudi Arabia.*

**Materials and Methods:** *276 patients aged  $\geq 8$  years were randomly selected and clinically examined for amalgam and resin composite restorations placed in permanent posterior teeth with living pulps by undergraduate dental students in university dental hospitals in Saudi Arabia. The restorations were placed in teeth preparations Class I and Class II. Also, bitewing and or periapical radiographs were used to define the depth of the cavity. The data obtained were documented in a patient examination form then statistically analyzed using Chi-Square Test or Fisher-Freeman-Halton Test.*

**Results:** *Composite was the main kind of restoration placed by dental students. There was an insignificant relationship between the kind of restoration (amalgam or composite) and the tooth type (maxillary/mandibular premolar and maxillary/mandibular molar), the class of tooth preparation, the cavity depth, the age of the patient, and the gender of the patient  $p > 0.05$ .*

**Conclusion:** *Composite was the most commonly restorative material used by dental students. Gradual reduction in the use of amalgam should be evidence-based. Students should obtain the necessary competencies for decision making according to each individual case.*

**Keywords:** *Amalgam, Composite, Class, Depth, Posterior, Type*

**Introduction****Amalgam**

Amalgam means an alloy of mercury (Hg) with any other metal. In dentistry, amalgam is the common term used to refer to dental amalgam which is an alloy made by mixing mercury with a silver-tin alloy (Ag-Sn) and used as a direct restorative material. Amalgam alloy is a silver-tin alloy with varying amounts of copper (Cu) and small amounts of zinc (Zn). There are low-copper amalgam alloys

and high-copper amalgam alloys. High-copper amalgam alloys display significantly better corrosion resistance than low-copper amalgam alloys. To use amalgam, the alloy particles are powerfully mixed with mercury (trituration) for a few seconds by an amalgamator (mechanical apparatus) or manually by a pestle and a mortar during the initial reaction. The mixture is condensed (condensation) into a tooth preparation to remove the excess mercury-rich phase.<sup>1</sup>

## Composite

A composite is a physical mixture of materials.<sup>1</sup> In dentistry, composite refers to dental resin composite which is a tooth-colored direct restorative material.<sup>2</sup> Composite is also called composite restorative material, composite resin, resin composite, resin-based composite.<sup>1</sup> The material consists of three components: resin matrix (organic content), fillers (inorganic part), and coupling agents.<sup>2</sup> The filler particles are distributed within the matrix phase. In most cases, the matrix phase is fluid at some point during the manufacture or fabrication of a composite system.<sup>1</sup> The fillers are made of quartz, ceramic, and or silica.<sup>2</sup> The filler particles provide mechanical reinforcement of the mixture and produce light transmission and light scattering that adds enamel-like translucency to the material, and the matrix flows to adapt to tooth preparation walls and penetrate into micromechanical spaces on etched enamel or dentin surfaces.<sup>1,2</sup>

## Materials and Methods

### Ethical approval:

The study was registered with the research center of Riyadh Elm University (FRP/2019/38) and received ethical approval from the institutional review board of the same institution (RC/IRB/2019/102).

### Selection of the content for analysis and statistical analysis

276 patients aged  $\geq 8$  years were randomly selected and clinically examined for amalgam and resin composite restorations placed in permanent posterior teeth with living pulps (nonendodontically treated) by undergraduate dental students in university dental hospitals in the Kingdom of Saudi Arabia. The study was conducted from April 2019 to August 2019. After taking the patient consent on an informed consent statement form for clinical studies, each patient was clinically examined in both the maxilla and the mandible for posterior composite and amalgam restorations placed in teeth

preparations according to Black's classification<sup>3</sup>: Class I and Class II (mesio-occlusal MO, disto-occlusal DO, mesio-occluso-distal MOD). Also, bitewing and or periapical radiographs (radiographic examination) were used to define the depth of the cavity which was recorded based on the American Dental Association Caries Classification System (ADA CCS)<sup>4</sup>:

**Initial:** (E1, E2, D1) Radiolucency may extend to the dentinoenamel junction or outer one-third of the dentin

E1(excluded from the present study): Radiolucency extends into the outer half of the enamel<sup>5</sup>

E2 (excluded from the present study): Radiolucency extends into the inner half of the enamel<sup>5</sup>

D1 (included in the present study): Radiolucency extends into the outer one-third of the dentin<sup>5</sup>

**Moderate:**

D2 (included in the present study): Radiolucency extends into the middle one-third of the dentin

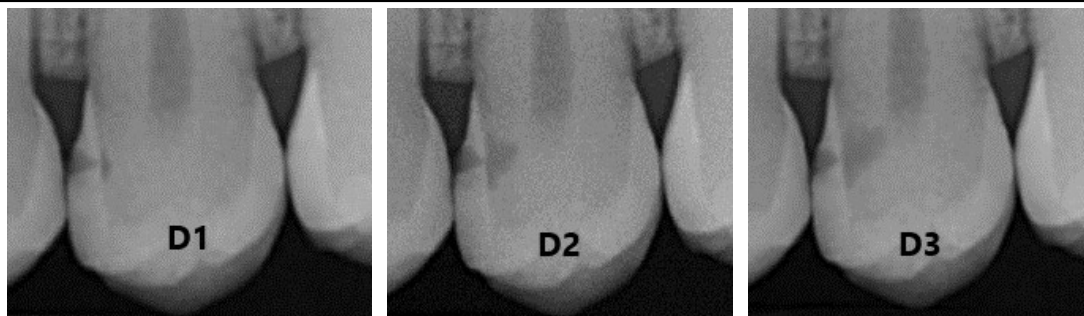
**Advanced:**

D3 (included in the present study): Radiolucency extends into the inner one-third of the dentin

Radiographs of D1, D2, and D3 are shown in Figure 1. Instead of radiolucency, radiopacity of the restoration was detected.

Posterior teeth were categorized into eight groups: maxillary first premolar, mandibular first premolar, maxillary second premolar, mandibular second premolar, maxillary first molar, mandibular first molar, maxillary second molar, mandibular second molar.

The data obtained including the age and the gender of the patient were documented in a patient examination form then statistically analyzed using Chi-Square Test or Fisher-Freeman-Halton Test when appropriate to test the association between categorical variables (restoration, age, gender, tooth type, cavity depth, class of tooth preparation). All statistical analyses were performed using the IBM SPSS Statistics version 20 data processing software. The significance level was set at  $p < 0.05$ .



**Figure 1:** Radiographs D1, D2, D3 Lesions

Source: American Dental Association Caries Classification System, 2015<sup>4</sup>

## Results

The sample of 276 patients consisted of males  $n=141$  (51.1%) and females  $n=135$  (48.9%). The age groups were as the following: 8-29 years  $n=130$  (47.1%), 30-40 years  $n=82$  (29.7%), 41-50  $n=43$  (15.6%), and  $\geq 51$   $n=21$  (7.6%).

## Amalgam and Composite

Chi-Square Test showed that there was a significant difference in the percentages (number of observations) of dental restorations (amalgam and composite)  $p=0.000<0.05$ , and composite was the predominant kind of restoration placed by dental students (Chart 1).

## Restoration and Tooth Type

Fisher's Exact Test showed that there was an insignificant relationship between the kind of restoration (amalgam or composite) and the tooth type (maxillary first premolar, mandibular first premolar, maxillary second premolar, mandibular second premolar, maxillary first molar, mandibular first molar, maxillary second molar, mandibular second molar)  $p=0.818>0.05$ .

## Restoration and class of tooth preparation Class I / Class II (MO, DO, MOD)

Fisher's Exact Test showed that there was an insignificant relationship between the kind of restoration (amalgam or composite) and the class of tooth preparation  $p=0.844>0.05$ .

## Restoration and Cavity Depth

Fisher's Exact Test showed that there was an insignificant relationship between the kind of

restoration (amalgam or composite) and the cavity depth (D1, D2, D3)  $p=0.919>0.05$ .

## Restoration and Patient Age

Fisher's Exact Test showed that there was an insignificant relationship between the kind of restoration (amalgam or composite) and the age of the patient  $p=0.475>0.05$ .

## Restoration and Patient Gender

Chi-Square Test showed that there was an insignificant relationship between the kind of restoration (amalgam or composite) and the gender of the patient (male/female)  $p=0.480>0.05$ .

## Discussion

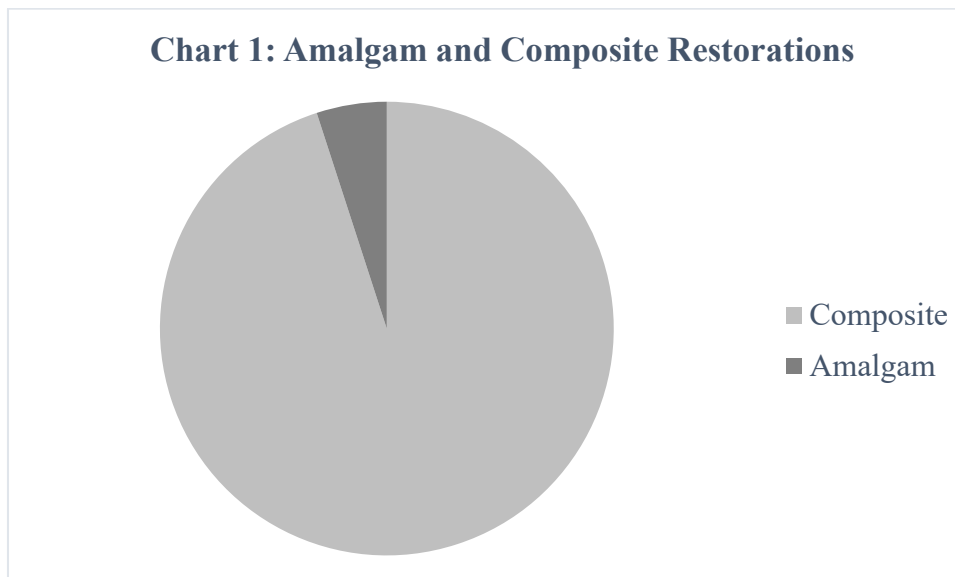
The most common reason for failure of posterior resin composite and amalgam restorations is secondary caries.<sup>6-11</sup> However, studies showed a higher risk of secondary caries in permanent posterior teeth restored with resin composite restorations compared with those restored with amalgam restorations.<sup>6,7,9,12</sup> For instance, in Burke et al. study, the majority of the respondents, 87% of respondents for composite and 91% of respondents for amalgam, reported that secondary caries was the main reason for replacement of amalgam and composite restorations.<sup>6</sup> Also, Bernardo et al. concluded that secondary caries was the main reason for failure in both posterior composite and amalgam restorations; however, risk of secondary caries was 3.5 times higher in composite restorations than in amalgam restorations.<sup>7</sup> In addition, the review of Rasines Alcaraz et al. showed that posterior resin composite restorations

had a higher risk of secondary caries than posterior amalgam restorations (risk ratio (RR) 2.14, 95% confidence interval (CI) 1.67 to 2.74).<sup>9</sup> Furthermore, Moraschini et al. stated that posterior composite restorations had a higher number of secondary caries when compared with amalgam restorations.<sup>12</sup> Another reason for failure of posterior resin composite and amalgam restorations is fracture<sup>10</sup>; however, Bernardo et al. found that there was no statistically significant difference between the two restorative materials in relation to fracture,<sup>7</sup> and Moraschini et al. found no statistically significant difference between the two restorative materials regarding the time of follow-up with respect to fracture.<sup>12</sup> Also, Rasines Alcaraz et al. found that posterior resin composite restorations didn't have an increased risk of restoration fracture compared with posterior amalgam restorations.<sup>9</sup>

Many studies agree that amalgam has a higher survival rate than resin composite. For instance, Bernardo et al. found that the survival rate of posterior amalgam restorations was 94.4%; that of posterior composite restorations was 85.5%. Annual

failure rates ranged from 0.16 to 2.83 percent for amalgam restorations and from 0.94 to 9.43 percent for composite restorations.<sup>7</sup> Also, Rasines Alcaraz et al. concluded that posterior resin composite restorations had a significantly higher risk of failure than amalgam restorations (risk ratio (RR) 1.89, 95% confidence interval (CI) 1.52 to 2.35).<sup>9</sup> In addition, Levin et al. observed higher failure rates in resin-based composite restorations than in amalgam restorations in posterior interproximal restorations.<sup>11</sup> Furthermore, Forss et al. found that the median ages of failed restorations were nearly 12 years for amalgam and slightly less than 5 years for composite.<sup>13</sup> In the same context, Moraschini et al. mentioned that resin composite restorations in posterior teeth still have less longevity,<sup>12</sup> and De Moor et al. stated that the survival of dental amalgam fillings is two times higher than composite fillings.<sup>14</sup> Also, Hickel et al. stated that the annual failure rate in posterior stress-bearing restorations is 0%-7% for amalgam and 0%-9% for direct composite.<sup>8</sup>

**Chart 1: Amalgam and Composite Restorations**



Gholampour et al. evaluated the effect of dental filling material and filling depth on the strength and deformation of filled teeth; the analyses were performed in two filling depths of 1/2 and 1/3 of the tooth height. Results showed that a 16.7% difference in filling depth led to a 8.9% stress

difference in the first molar filled with composite; however, the effect of depth on the level of stress in the tooth filled with amalgam was not considerable. For composite fillings, the amount of tooth deformation increased in the first molar for the filling depths 1/2 and 1/3 of the tooth height, while

it was small for amalgam fillings in both filling depths. The first molar filled with composite was 13.7% weaker than the normal tooth, while it was almost as strong as a normal tooth when it was filled with amalgam. The study concluded that amalgam was a more proper dental filling material for the first molar although a 16.7% change in drilling depth is needed for tooth preparation.<sup>15</sup>

In Great Britain, 49% of dentists rarely or never place large composite restorations in posterior teeth; clinical indications and patients' demands are the driving force for their choice of the material. Reasons for not using composite materials in load-bearing situations included: poorer wear resistance than amalgam, difficulties in manipulation, less good value for money for the patient, increased number of symptoms with composite, more time-consuming placement, and reduced longevity.<sup>6</sup>

In Brazil, dental schools have been changing from amalgam towards placing resin composite in posterior teeth which has not been followed by the Public Health Dental System. For instance, Parolo et al. found that a higher number of amalgam fillings was placed in posterior teeth in public health service in comparison to two dental schools (Federal University of Rio Grande do Sul and Lutheran University of Brazil) where composite resin restorations dominated.<sup>16</sup> Also, in Brazil, Terada et al. found that the majority of restorations were performed with amalgam in 10 basic health units, whereas there was higher prevalence of resin composite restorations at a public dental school.<sup>17</sup> In addition, in the United States, Canada, the United Kingdom, and Ireland, there has been an inclination towards increasing the teaching of posterior composites in recent years; however, the proportion of posterior composite restorations placed by dental students relative to dental amalgams does not yet match the typical situation in contemporary clinical practice.<sup>18</sup> Furthermore, in Saudi Arabia, Pani et al. found that the majority of undergraduate students regardless of the type of school preferred posterior resin composite over amalgam. Students in both the private and the government college were likely to give higher scores for composite than amalgam.

Although the majority of students in both schools felt that amalgam could not be completely replaced by composite, a higher number of students in the private school than in the public school felt that amalgam would be replaced by composite resin restorations. In the opinion of the respondents, the main drawback of amalgam was lack of esthetics, while it was micro-leakage for composite.<sup>19</sup>

Moreover, in Saudi Arabia, Alkhudhairy conducted a study that targeted dentists and interns working in both private and public sectors. The results of the study indicated that compared with dentists, a significantly higher number of interns did not use amalgam in their clinical practice frequently, agreed on replacing a good amalgam restoration with resin composite, and on stopping the use of amalgam as a final restoration. Esthetics was the reason for the majority of interns 76.1% and dentists 78.7% for restricting the use of dental amalgam. However, if a patient had a defective amalgam restoration, the majority of interns 87.8% and dentists 74.3% preferred replacing it with dental amalgam rather than composite material. Alkhudhairy concluded that fresh dental graduates used amalgam less frequently compared with experienced dentists in Riyadh, Saudi Arabia.<sup>20</sup>

In Finland, resin composite was used in 74.9% of restorations and was the most common restorative material, whereas amalgam was used in 4.8% of restorations.<sup>13</sup> According to Forss et al., although clinical dentistry in Finland has moved towards the post-amalgam era, the functional periods of the failed tooth-colored restorations are disappointingly short and warrant some serious consideration.<sup>13</sup>

Also, Bernardo et al. concluded that the difference in performance of posterior composite and amalgam restorations was accentuated in large restorations and in those with more than three surfaces involved.<sup>7</sup> If longevity is the primary criterion in material selection, amalgam appears to be preferable to be used in multi-surface restorations of large posterior teeth,<sup>7</sup> and a dentist should place resin composite fillings only in small to moderately sized cavities because despite of developments, composite restorations use in occlusal load-bearing restorations

should be viewed with caution since they are technically much more demanding than amalgam and may not maintain occlusal contacts as well. They have acceptable wear characteristics in small cavities, but loss may be seen in larger cavities surface within approximately five years; also, marginal breakdown may be associated with the occlusion and the late effects of polymerization shrinkage.<sup>21</sup>

In the present study, it was observed that resin composite restorations were more frequently placed in permanent posterior teeth than amalgam restorations regardless of the cavity depth, class of tooth preparation, tooth type, arch, patient age, and patient gender. Gradual reduction in the use of amalgam is possible. However, it should be done according to evidence-based research that investigates the technical properties and clinical applications of new composite generations in relation to many factors such as the size and depth of cavity, class of cavity preparation, tooth type, and arch. Also, dental schools have a responsibility to ensure that their curricula are evidence-based to best prepare their students develop the necessary competencies for critical thinking and decision making according to each individual case in order to meet the needs and expectations of their future patients in their clinical practice.<sup>17,18</sup>

### Conclusion

The results of this study indicated that resin composite was the most commonly restorative material placed in permanent posterior teeth by undergraduate dental students in university teaching hospitals in Saudi Arabia. It was placed regardless of the cavity depth, class of tooth preparation, tooth type, patient age, and patient gender.

**Funding:** None

**Conflict of interest:** None declared

### References

1. Bayne SC, Thompson JY. Biomaterials. In: Roberson TM, Heymann HO, Swift Jr EJ, editors. *Sturdevant's Art and Science of Operative*

*Dentistry*. 5<sup>th</sup> ed. St. Louis, Missouri: Mosby Elsevier; 2006:137-242.

2. Zimmerli B, Strub M, Jeger F, Stadler O, Lussi A. Composite materials: composition, properties and clinical applications. *Schweiz Monatsschr Zahnmed*. 2010;120(11):972-979.

3. Roberson TM. Fundamentals in tooth preparation. In: Roberson TM, Heymann HO, Swift Jr EJ, editors. *Sturdevant's Art and Science of Operative Dentistry*. 5<sup>th</sup> ed. St. Louis, Missouri: Mosby Elsevier; 2006:283-321.

4. Young DA, Nový BB, Zeller GG, Hale R, Hart TC, Truelove EL. The American Dental Association caries classification system for clinical practice: a report of the American Dental Association Council on Scientific Affairs. *J Am Dent Assoc*. 2015;146(2):80-86.

5. Anusavice KJ. Present and future approaches for the control of caries. *J Dent Educ*. 2005;69(5):538-554.

6. Burke FJ, McHugh S, Hall AC, Randall RC, Widstrom E, Forss H. Amalgam and composite use in UK general dental practice in 2001. *Br Dent J*. 2003;194(11): 613–618.

7. Bernardo M, Luis H, Martin MD, et al. Survival and reasons for failure of amalgam versus composite posterior restorations placed in a randomized clinical trial. *J Am Dent Assoc*. 2007;138(6):775-783.

8. Hickel R, Manhart J. Longevity of restorations in posterior teeth and reasons for failure. *J Adhes Dent*. 2001;3(1):45-64.

9. Rasines Alcaraz MG, Veitz-Keenan A, Sahrman P, Schmidlin PR, Davis D, Iheozor-Ejiofor Z. Direct composite resin fillings versus amalgam fillings for permanent or adult posterior teeth. *Cochrane Database Syst Rev*. 2014; (3).

10. Opdam NJ, Van de Sande FH, Bronkhorst E, et al. Longevity of posterior composite restorations: a systematic review and meta-analysis. *J Dent Res*. 2014;93(10):943-949.

11. Levin L, Coval M, Geiger SB. Cross-sectional radiographic survey of amalgam and resin-based

- composite posterior restorations. *Quintessence Int.* 2007;38(6):511-514.
12. Moraschini V, Fai CK, Alto RM, Dos Santos GO. Amalgam and resin composite longevity of posterior restorations: a systematic review and meta-analysis. *J Dent.* 2015;43(9):1043-1050.
13. Forss H, Widström E. From amalgam to composite: selection of restorative materials and restoration longevity in Finland. *Acta Odontol Scand.* 2001;59(2):57–62.
14. De Moor R, Delmé K. [Black or white--Which choice for the molars? Part 2. Which does one choose for the restoration of posterior teeth: amalgam or composite?]. *Rev Belge Med Dent (1984).* 2008;63(4):135-146.
15. Gholampour S, Zoorazma G, Shakouri E. Evaluating the effect of dental filling material and filling depth on the strength and deformation of filled teeth. *J Dent Mater Tech.* 2016;5(4):172-180.
16. Parolo CF, Macarevich A, Juliana JJ, Maltz M. Amalgam versus resin composite for the restoration of posterior teeth: disparities between public clinical practice and dental education in Southern Brazil. *Rev Fac Odontol Porto Alegre.* 2011;52(1/3):33-37.
17. Terada RS, Maiolino R, Barbana MD, Costa MC, Damasceno SM, Fujimaki M. Beyond the discourse of amalgam vs composite resin restorations. *RGO Rev Gaúch Odontol.* 2014;62(2):137-142.
18. Lynch CD, McConnell RJ, Wilson NH. Trends in the placement of posterior composites in dental schools. *J Dent Educ.* 2006;71(3):430-434.
19. Pani SC, Al Abbassi MF, Al Saffan AD, Al Sumait MA, Shakir AN. Factors influencing Saudi dental students' preference of amalgam or composite for posterior dental restorations. *S J Oral Sci.* 2014;1(1):30-36.
20. Alkhudhairy F. Attitudes of dentists and interns in Riyadh to the use of dental amalgam. *BMC Res Notes.* 2016;9:488.
21. Jacobsen P. Intracoronal restorations. In: Jacobsen P, editor. *Restorative Dentistry: an Integrated Approach.* 2<sup>nd</sup> ed. Oxford: Wiley-Blackwell Publishing; 2008:91-106.